

# Febrile Seizures and Genetic Epilepsy Syndromes

---

JOSEPH HARMON DO

NEUROLOGY UPDATE 2016

UNIVERSITY OF NEW MEXICO CONTINUUM OF CARE CLINIC

05 FEBRUARY 2016

# Goals of Presentation

---

Review basics of seizures and epilepsy

Learn about febrile seizures

Discuss approach to seizures in children

Become familiar with epilepsy syndromes

Overview of genetics of epilepsy



# Reviewing the Basics

---

## Seizure:

- Sudden disruption of the brain's normal electrical activity.
- Accompanied by altered consciousness, disruption in motor or sensory systems.
- Can be subtle or "silent" (sub-clinical).
- Many different types of seizures.
  - Generalized vs focal
  - Tonic, tonic-clonic, myoclonic, atonic, absence



## Epilepsy:

- In 3 words

RECURRENT

NONPROVOKED

SEIZURES

# Reviewing the Basics

---

10%

1%

# General approach to childhood seizures

---

## Initial diagnostic evaluation-- “4 questions”

1. Seizure confirmation: “Are the events seizures?”
2. Seizure classification: “Where on the surface of the brain does the seizure originate?”
3. Epilepsy classification: “What is the etiology for these seizures?”
4. Syndrome identification: “Do the seizures and other patient-specific symptoms (eg, age of onset, EEG pattern, developmental status) fit a recognizable pattern?”

# 1- Seizure Confirmation

---

Million dollar question #1: Are the events epileptic in nature?

There are many seizure mimickers in children:

- Syncope
- Tics
- Inattentiveness
- Migraine
- Behavioral events

Establishing diagnosis is of paramount importance:

- Non-epileptic seizures do not respond to seizure medications
- Delay in diagnosis results in delay of appropriate treatment
- More difficult to stop an AED than to start one



# 1- Seizure Confirmation

---


Million dollar question #2: How can I know if the events are epileptic?

## HISTORY!

- Detailed history of events, sequential from before event started to after.
- Helpful if parent can video record event.
- Factors leading toward epileptic seizure vs non-epileptic event?

## EEG!

- Only diagnostic study uniformly recommended after new-onset seizure.
- Prolonged or routine?
- Do we have to capture a spell?

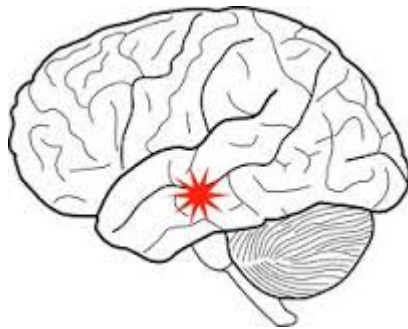


# 2- Seizure Classification

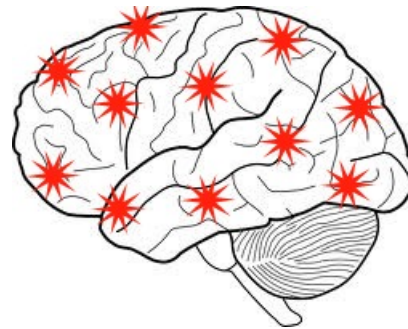---

Where in the brain do the seizures originate?

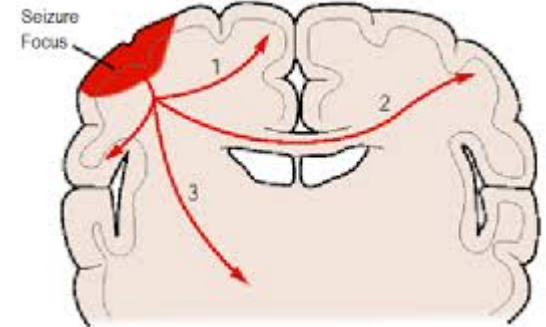
**Focal**



**Generalized**



\*\*\*Some seizures have focal onset with “secondary generalization”





# 2- Seizure Classification

---

Why important to distinguish focal or generalized?

- may influence work-up (more likely to get MRI if focal onset)
- ~~may~~ will influence medical management (focal drugs vs generalized drugs)
- potential surgery (focal resection, hemispherectomy, corpus callosotomy, etc)

# 2- Seizure Classification

“Simple partial” =  
focal seizure without  
impairment of consciousness

“Complex partial” =  
focal seizure with impairment  
of consciousness =  
“focal dyscognitive”


**TABLE 1-4 Seizure Types and Terminology Used in the 1981 Classification of Seizures and Recommended in the 2010 Report<sup>a,b</sup>**

Mode of Onset	1981 Seizure Types <sup>c</sup>	2010 Seizure Descriptions <sup>d</sup>
Focal	Simple partial With motor signs With sensory symptoms With autonomic symptoms With psychic symptoms (but no impaired consciousness)	Without impairment of consciousness or awareness: With observable motor or autonomic components Involving subjective sensory or psychic phenomena only, corresponding to the concept of an aura
	Complex partial Consciousness impaired at onset Simple partial onset followed by impairment of consciousness	With impairment of consciousness or awareness. <i>Dyscognitive</i> is a term that has been proposed for this concept. <sup>21</sup>
	Partial evolving to secondarily generalized seizure (tonic, clonic, or tonic-clonic) Simple evolving to generalized tonic-clonic Complex evolving to generalized tonic-clonic (including those with simple partial onset)	Evolving to a bilateral, convulsive seizure (involving tonic, clonic, or tonic and clonic components).
Generalized onset	Tonic-clonic Myoclonic	Tonic-clonic (in any combination) Myoclonic Myoclonic Myoclonic-atonic Myoclonic-tonic
	Absence With various accompanying manifestations Atypical	Absence Typical absence Atypical absence With special features Eyelid myoclonia <sup>e</sup> Myoclonic absence
	Clonic Tonic Atonic (astatic)	Clonic Tonic Atonic
	Not clear	Anything that does not fit in above, eg, rhythmic eye movements, chewing, swimming movements

<sup>a</sup> Data from Commission on Classification and Terminology of the International League Against Epilepsy. *Epilepsia*.<sup>3</sup> [onlinelibrary.wiley.com/doi/10.1111/j.1528-1157.1981.tb06159.x#abstract](http://onlinelibrary.wiley.com/doi/10.1111/j.1528-1157.1981.tb06159.x#abstract).  
<sup>b</sup> Data from Data from Berg AT, et al. *Epilepsia*.<sup>5</sup> [onlinelibrary.wiley.com/doi/10.1111/j.1528-1167.2010.02522.x/full](http://onlinelibrary.wiley.com/doi/10.1111/j.1528-1167.2010.02522.x/full).  
<sup>c</sup> The order has been rearranged to correspond to the order in the 2010 report.  
<sup>d</sup> See **Table 1-5** for a more complete listing of semiologic features relevant to describing any type of seizure.  
<sup>e</sup> Many have commented that pure eyelid myoclonia should have been considered as a myoclonic seizure and not an absence seizure.

# Generalized Tonic-Clonic Seizure


---



<https://www.youtube.com/watch?v=axOSChJWEHA>

# Generalized Tonic Seizure


---



<https://www.youtube.com/watch?v=pjmDY3tR6ak>

# Generalized Absence Seizure


---



<https://www.youtube.com/watch?v=obbg1BFt26Q>

# Generalized Atonic Seizure

---



<https://www.youtube.com/watch?v=9obFVWW47NE>

# Epilepsy Action

UK charity

<http://epilepsy.org.uk/>

<http://learn.epilepsy.org.uk/training-for-schools>

The screenshot shows the 'epilepsy action Learning' website. At the top right is a 'Log in to the site' link. A navigation bar contains 'Home', 'Epilepsy: the basics', 'Courses', and 'About'. The main content area features a 'Training for schools' section with the text: 'We have a range of training resources for people working in schools, to help you learn how to best support pupils with epilepsy.' Below this are three buttons: 'First aid for seizures at school: videos', 'Online training for the whole school', and 'Online training and resources for teachers'. A fourth button, 'Download and print a letter to take into school', spans across the bottom of these three. To the right is a 'Quick links' sidebar with three items: 'Main Epilepsy Action site', 'Become a member of Epilepsy Action', and 'Contact us'. Below the buttons is a section titled 'First aid for seizures in schools' with an image of a teacher and a student in a classroom. Below the image is the text: 'Watch our short films showing what you need to do if a pupil has a seizure in schools. They cover focal, tonic-clonic, absence, myoclonic, tonic, and atonic seizures.'

# Epilepsy Support in ABQ?

---

Epilepsy Support & Educational Services  
epilepsysupportnm.org  
epilepsyNM@gmail.com  
(505) 243-9119

Epilepsy Walk

Saturday, March 26<sup>th</sup>

9 AM – Noon

Tiguex Park (near ABQ Museum of Art, Natural History, Explora)



# 3- Epilepsy Classification (Etiology)

---

International League Against Epilepsy (ILAE) classification

Old classification:

- Idiopathic (primary) – presumed genetic etiology
- Symptomatic (secondary) – known or presumed structural or metabolic abnormality
- Cryptogenic – presumed symptomatic but etiology not known

2010 ILAE proposed revision:

- Genetic
- Structural/Metabolic
- Unknown



clear as mud

# 3- Epilepsy Classification

Idiopathic = genetic

Symptomatic = structural/metabolic

Cryptogenic = unknown

**TABLE 1-1** New Terminology and Concepts Contrasted With Older Terminology

Old Term and Definition <sup>a</sup>	New Term and Concept/Definition <sup>b</sup>	Rationale for New Terminology
<b>Idiopathic:</b> No underlying cause other than a possible hereditary predisposition exists. Idiopathic epilepsies are defined by age-related onset, clinical and electroencephalographic characteristics, and a presumed genetic etiology.	<b>Genetic:</b> Epilepsy is the direct result of a known or presumed genetic defect(s) in which seizures are the core symptom of the disorder. The knowledge regarding the genetic contributions may derive from specific molecular genetic studies that have been well replicated and even become the basis of diagnostic tests or the evidence for a central role of a genetic component may come from appropriately designed family studies.	The notion that epilepsy has no cause and that a genetic predisposition can only be presumed is antiquated. Further, the term idiopathic was used for disorders that did not have clear evidence of a genetic basis but were self-limited and had an excellent prognosis and no major associated disability. Thus, idiopathic was used to connote benign.
<b>Symptomatic:</b> Symptomatic epilepsies and syndromes are considered the consequence of a known or suspected disorder of the CNS.	<b>Structural/metabolic:</b> A distinct structural or metabolic condition or disease has been demonstrated to be associated with a substantially increased risk of developing epilepsy in appropriately designed studies.	All epilepsies and seizures are caused by something, thus the definition of symptomatic is circular. In practice it was used to infer an underlying brain lesion and also connoted bad outcome. As various genetic encephalopathies have been reported recently, this definition is at odds with the current scientific literature.
<b>Cryptogenic:</b> Refers to a disorder whose cause is hidden or occult. Cryptogenic epilepsies are presumed to be symptomatic, but the etiology is not known.	<b>Unknown:</b> Meant to be viewed neutrally and to designate that the nature of the underlying cause is as yet unknown; it may have a fundamental genetic defect at its core or it may be the consequence of a separate or unrecognized disorder.	Many of the formerly cryptogenic epilepsies have been shown to have a genetic basis (eg, Dravet syndrome, autosomal dominant nocturnal frontal lobe epilepsy). Rather than feign knowledge about a symptomatic cause, the preference is to say that the cause is unknown.

<sup>a</sup> Data from Commission on Classification and Terminology of the International League Against Epilepsy, Epilepsia.<sup>4</sup> [onlinelibrary.wiley.com/doi/10.1111/j.1528-1157.1989.tb05316.x/abstract](http://onlinelibrary.wiley.com/doi/10.1111/j.1528-1157.1989.tb05316.x/abstract).

<sup>b</sup> Data from Berg AT, et al, Epilepsia.<sup>5</sup> [onlinelibrary.wiley.com/doi/10.1111/j.1528-1167.2010.02522.x/full](http://onlinelibrary.wiley.com/doi/10.1111/j.1528-1167.2010.02522.x/full).

# Febrile Seizures

---

A febrile seizure is a seizure accompanied by **fever** (temperature  $\geq 100.4^{\circ}\text{F}$  or  $38^{\circ}\text{C}$  by any method), **without** central nervous system infection, that occurs in infants and children **6 through 60** months of age. Febrile seizures occur in **2% to 5%** of all children and, as such, make up the most common convulsive event in children younger than 60 months.

# Febrile Seizures

---

6 months – 6 years

Fever (BUT NO CNS INFECTION)

Developmentally normal

Before 6 months? NOT A FEBRILE SEIZURE

After 6 years? NOT A FEBRILE SEIZURE



# Simple Febrile Seizure

---

## Criteria:

primary generalized seizure

last less than 15 minutes

no recurrence in 24 hour period (or during duration of febrile illness)

# Simple Febrile Seizure

---

Recommended work-up?

Labs?

Lumbar Puncture?

EEG?

MRI?

“Identify the cause of the fever”

Why important identify fever?

Management for viral syndrome vs UTI vs otitis media vs meningitis

# Simple Febrile Seizure

AAP Practice Guidelines from 2011

Subcommittee on Febrile Seizures:

- child neurologist (chair)
- neuroepidemiologist
- 3 additional child neurologists
- practicing pediatrician

Methodology:

- Comprehensive review of evidence-based literature from 1996 to 2009.
- 500+ articles reviewed.
- 70 articles which best fit criteria selected.

**PEDIATRICS**  
OFFICIAL JOURNAL OF THE AMERICAN ACADEMY OF PEDIATRICS

Home | About | Current Issue | AAP Policy | eArchives | Supplements | Collections | eLetters | Early Release

Institution: UNM Health Sciences Library and Informatics Center

« Previous | Next Article »  
Table of Contents

**From the American Academy of Pediatrics**  
Clinical Practice Guideline

**Febrile Seizures: Guideline for the Neurodiagnostic Evaluation of the Child With a Simple Febrile Seizure**

Subcommittee on Febrile Seizures

**This Article**  
PEDIATRICS Vol. 127 No. 2 February 1, 2011  
pp. 385-394  
(doi: 10.1542/peds.2010-3318)

- Abstract *Free*
- » Full Text *Free*
- Full Text (PDF) *Free*

- Article Type

Evidence Quality	Preponderance of Benefit or Harm	Balance of Benefit and Harm
A. Well-designed RCTs or diagnostic studies on relevant population	<b>Strong</b>	<b>Option</b>
B. RCTs or diagnostic studies with minor limitations; overwhelmingly consistent evidence from observational studies	<b>Rec</b>	<b>Option</b>
C. Observational studies (case-control and cohort design)	<b>Option</b>	<b>No Rec</b>
D. Expert opinion, case reports, reasoning from first principles	<b>Option</b>	<b>No Rec</b>
X. Exceptional situations for which validating studies cannot be performed and there is a clear preponderance of benefit or harm	<b>Strong Rec</b>	

# Simple Febrile Seizure

---

## Key Action Statements from AAP Guidelines:

### Action Statement 1— Lumbar Puncture *Action Statement 1a*

A **lumbar puncture should be performed** in any child who presents with a seizure and a fever and has **meningeal signs and symptoms** (eg, neck stiffness, Kernig and/or Brudzinski signs) or in any child whose **history or examination suggests** the presence of meningitis or intracranial infection.

**Aggregate evidence level: B (overwhelming evidence from observational studies).**

**Benefits:** Meningeal signs and symptoms strongly suggest meningitis, which, if bacterial in etiology, will likely be fatal if left untreated.

**Harms/risks/costs:** Lumbar puncture is an invasive and often painful procedure and can be costly.

**Benefits/harms assessment:** Preponderance of **benefit over harm**.

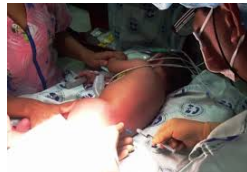**Value judgments:** Observational data and clinical principles were used in making this judgment.

**Role of patient preferences:** Although parents may not wish to have their child undergo a lumbar puncture, health care providers should explain that if meningitis is not diagnosed and treated, it could be fatal.

**Exclusions:** None.

**Intentional vagueness:** None.

**Policy level: Strong recommendation.**





# Simple Febrile Seizure

---

Key Action Statements from AAP Guidelines:

**Action Statement 1— Lumbar Puncture**  
*Action Statement 1b*

In any infant between 6 and 12 months of age who presents with a seizure and fever, a **lumbar puncture is an option** when the child is considered **deficient in *Haemophilus influenzae type b (Hib)* or *Streptococcus pneumoniae* immunizations** (ie, has not received scheduled immunizations as recommended) or when immunization status cannot be determined because of an increased risk of bacterial meningitis.

**Aggregate evidence level: D (expert opinion, case reports).**

Benefits: Meningeal signs and symptoms strongly suggest meningitis, which, if bacterial in etiology, will likely be fatal or cause significant long-term disability if left untreated.

Harms/risks/costs: Lumbar puncture is an invasive and often painful procedure and can be costly.

Benefits/harms assessment: Preponderance of benefit over harm.

Value judgments: Data on the incidence of bacterial meningitis from before and after the existence of immunizations against *H. influenzae type b* and *S. pneumoniae* were used in making this recommendation.

Role of patient preferences: Although parents may not wish their child to undergo a lumbar puncture, health care providers should explain that in the absence of complete immunizations, their child may be at risk of having fatal bacterial meningitis.

Exclusions: This recommendation applies only to children 6 to 12 months of age. The subcommittee felt that clinicians would recognize symptoms of meningitis in children older than 12 months.

Intentional vagueness: None.

**Policy level: Option.**



# Simple Febrile Seizure

---

Key Action Statements from AAP Guidelines:

**Action Statement 1— Lumbar Puncture**  
*Action Statement 1c*

A **lumbar puncture is an option** in the child who presents with a seizure and fever and is **pretreated with antibiotics**, because antibiotic treatment can mask the signs and symptoms of meningitis.

**Aggregate evidence level: D (reasoning from clinical experience, case series).**

Benefits: Antibiotics may mask meningeal signs and symptoms but may be insufficient to eradicate meningitis; a diagnosis of meningitis, if bacterial in etiology, will likely be fatal if left untreated.

Harms/risks/costs: Lumbar puncture is an invasive and often painful procedure and can be costly.

Benefits/harms assessment: Preponderance of benefit over harm.

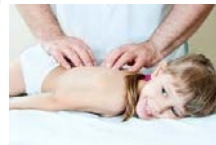Value judgments: Clinical experience and case series were used in making this judgment while recognizing that extensive data from studies are lacking.

Role of patient preferences: Although parents may not wish to have their child undergo a lumbar puncture, medical providers should explain that in the presence of pretreatment with antibiotics, the signs and symptoms of meningitis may be masked. Meningitis, if untreated, can be fatal.

Exclusions: None.

Intentional vagueness: Data are insufficient to define the specific treatment duration necessary to mask signs and symptoms. The committee determined that the decision to perform a lumbar puncture will depend on the type and duration of antibiotics administered before the seizure and should be left to the individual clinician.

**Policy level: Option.**



# Simple Febrile Seizure

---

## Key Action Statements from AAP Guidelines:

### Action Statement 2– EEG

An electroencephalogram (EEG) **should not be performed** in the evaluation of a neurologically healthy child with a simple febrile seizure.

**Aggregate evidence level: B (overwhelming evidence from observational studies).**

Benefits: One study showed a possible association with paroxysmal EEGs and a higher rate of afebrile seizures.

Harms/risks/costs: EEGs are costly and may increase parental anxiety.

Benefits/harms assessment: Preponderance of **harm over benefit**.

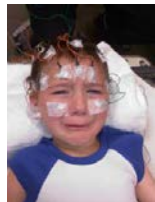Value judgments: Observational data were used for this judgment.

Role of patient preferences: Although an EEG might have limited prognostic utility in this situation, parents should be educated that the study will not alter outcome.

Exclusions: None.

Intentional vagueness: None.

**Policy level: Strong recommendation.**



# Simple Febrile Seizure

---

## Key Action Statements from AAP Guidelines:

### Action Statement 3– Lab studies

The **following tests should not be performed** routinely for the sole purpose of identifying the cause of a simple febrile seizure: measurement of serum **electrolytes, calcium, phosphorus, magnesium, or blood glucose or complete blood cell count**.

**Aggregate evidence level: B (overwhelming evidence from observational studies).**

**Benefits:** A complete blood cell count may identify children at risk for bacteremia; however, the incidence of bacteremia in febrile children younger than 24 months is the same with or without febrile seizures.

**Harms/risks/costs:** Laboratory tests may be invasive and costly and provide no real benefit.

**Benefits/harms assessment:** Preponderance of **harm over benefit**.

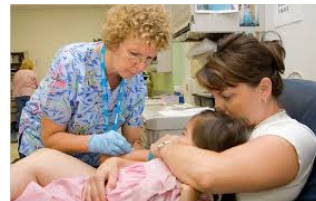**Value judgments:** Observational data were used for this judgment.

**Role of patient preferences:** Although parents may want blood tests performed to explain the seizure, they should be reassured that blood tests should be directed toward identifying the source of their child's fever.

**Exclusions:** None.

**Intentional vagueness:** None.

**Policy level: Strong recommendation.**



# Simple Febrile Seizure

---

## Key Action Statements from AAP Guidelines:

### Action Statement 4– MRI

**Neuroimaging should not be performed** in the routine evaluation of the child with a simple febrile seizure.

**Aggregate evidence level: B (overwhelming evidence from observational studies).**

Benefits: Neuroimaging might provide earlier detection of fixed structural lesions, such as dysplasia, or very rarely, abscesses or tumor.

Harms/risks/costs: Neuroimaging tests are costly, computed tomography (CT) exposes children to radiation, and MRI may require sedation.

Benefits/harms assessment: Preponderance of **harm over benefit**.

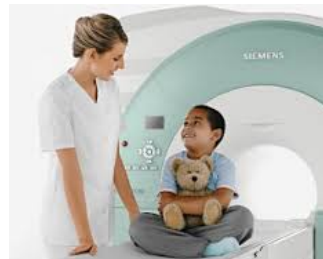Value judgments: Observational data were used for this judgment.

Role of patient preferences: Although parents may want neuroimaging performed to explain the seizure, they should be reassured that the tests carry risks and will not alter outcome for their child.

Exclusions: None.

Intentional vagueness: None.

**Policy level: Strong recommendation.**



# Simple Febrile Seizure

---

## Prognosis?

- No increased risk of mortality, hemiplegia, or mental retardation.
- Risk of recurrent febrile seizure about **33%**.
- Risk of epilepsy "only slightly higher than that of general population".
  - **1% → 2%**
- Overall-- "benign events with excellent prognoses".

# Simple Febrile Seizure

---

Time to find out who was paying attention!

Labs?

Lumbar Puncture?

EEG?

MRI?

# Complex Febrile Seizure

---

Criteria:

- **Longer** than 15 minutes
- **Focal** onset
- **Recurrence** within 24 hours (or duration of febrile illness)

\*or history of epilepsy (recurrent nonprovoked seizures)



# Complex Febrile Seizure

---

Febrile seizures affect \_\_\_\_\_ to \_\_\_\_\_ percent of all children?

2 to 5%<sup>1</sup>

What percentage of febrile seizures are “complex”?

25 to 30%<sup>2</sup>

What percentage of patients with *simple* febrile seizures develop epilepsy?

2%<sup>1</sup>

What percentage of patients with *complex* febrile seizures develop epilepsy

6-8% with 1 feature of CFS,

17-22% with 2 features,

49% with all 3 features.<sup>3</sup>

# Complex Febrile Seizure

---

So what is the work-up for patients with CFS anyway?

Are there any handy AAP practice guidelines?

# Complex Febrile Seizure

---

Recent survey of 353 pediatric emergency medicine physicians in 10 US hospitals<sup>4</sup>

Methodology:

- Volunteer participation through pediatric emergency medicine physician listserv
- 5 hypothetical cases presented
- Questionnaire regarding work-up, admission, treatment following hypothetical cases

Study revealed:

- 54% would obtain blood tests.
- 62% would obtain urine.
- 34% would perform lumbar puncture.
- 36% would perform neuroimaging.

Conclusion: Significant variability in the work-up of patients with CFS.

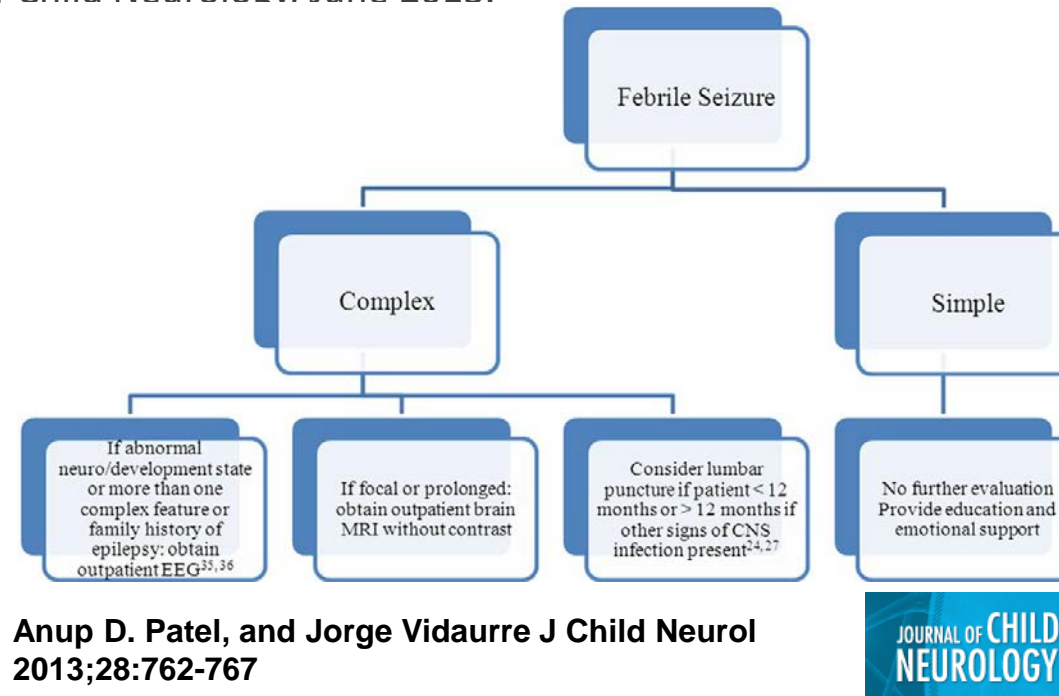
Potential problems with this survey?

# Complex Febrile Seizure

Recent paper from Patel and Vidaurre from Nationwide Children's Hospital

-Proposed work-up for patients with complex febrile seizures.

-Published in Journal of Child Neurology. June 2013.<sup>5</sup>



Anup D. Patel, and Jorge Vidaurre J Child Neurol  
2013;28:762-767

# Complex Febrile Seizure

---

Work-up for recurrent febrile seizure (2 or more generalized seizures during febrile illness)?

Work-up for prolonged (>15 minute) generalized febrile seizure?

Work-up for focal onset febrile seizure?

Work-up for any 2 of the 3?

Work-up for all 3?

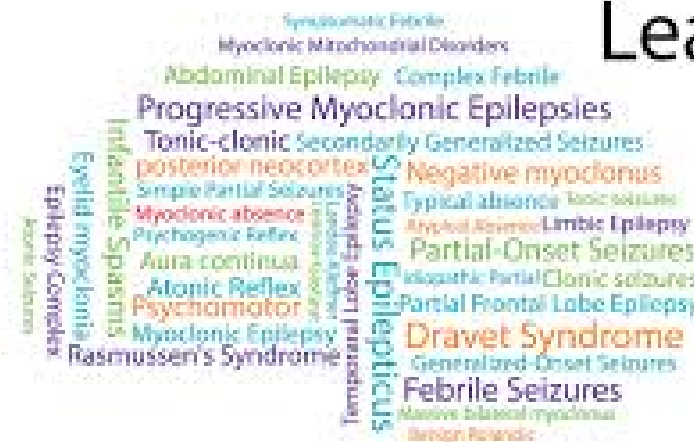# 4- Epilepsy Syndromes

---

“...a complex of signs and symptoms that define a unique epileptic condition...” (ILAE)

Patients with similar:

- age of onset
- seizure type(s)
- progression of seizures
- EEG findings
- developmental comorbidities
- genetic changes
- pathophysiologic mechanisms
- response to treatment



Learn about  
Epilepsy  
Syndromes

# 4- Epilepsy Syndromes

---

Why important diagnose specific epilepsy syndrome?

Guidance in treatment

Surveillance for comorbidities

Long-term prognostic information

Genetic information (recurrence risk)

# Continuing on with febrile seizure spectrum

---

## Generalized (Genetic) Epilepsy Febrile Seizures Plus (**GEFS+**):

- Primary generalized epilepsy syndrome characterized by both **febrile and afebrile** seizures.
- AD condition with incomplete penetrance (60-80%) and genetic heterogeneity.
- Prior to onset of afebrile seizures, **GEFS+ difficult to distinguish from febrile seizures**, detailed family history helps distinguish.
- **Multiple genes** linked including **SCN1A** (sodium channel).
  - 90+ different mutations leading to hyperexcitation or hypoexcitation of channel.
  - Other genes include **SCN1B**, **GABRG2** (GABA receptor gamma subunit), **PCDH19** (calcium channel).
- Prognosis is generally good— spontaneous remission of seizures by age 11 years in many.
  - Up to 30% have more prolonged and severe epilepsy.



# Is GEFS+ a real entity?

---

“GEFS+” more accurately is a spectrum of fever-associated infantile and childhood epilepsy syndromes.

GEFS+ conditions range from more benign conditions (febrile seizures) to more malignant syndromes such as:

- Severe myoclonic epilepsy of infancy (SMEI)
  - AKA **Dravet Syndrome**
- Borderline SMEI (SMEB)
- Intractable epilepsy of childhood (IEC)

# Dravet Syndrome (severe myoclonic epilepsy of infancy)

---

Onset in first year of life in a previously well child.

Often begin with febrile seizure (febrile status epilepticus not uncommon).

Seizures can be generalized or focal onset.

Triggered by **fever, infection, vaccination, bath.**

Progression to recurrent, prolonged, and focal seizures.

Diagnosis is clinical, but genetic testing supportive.

~80% of cases have mutation in **SCN1A** gene, majority represent sporadic mutation.

Treatment-- Valproic acid +/- clobazam or stiripentol. Good response to **ketogenic diet.**

Prognosis is poor:

- Seizures are **refractory** to treatment.
- **Developmental stagnation** and regression occurs.
- Mortality rate 16 to 18%, due to status epilepticus, SUDEP, drowning.

# Dravet Syndrome

---

*SCN1A* mutation present in 80% patients with Dravet syndrome.

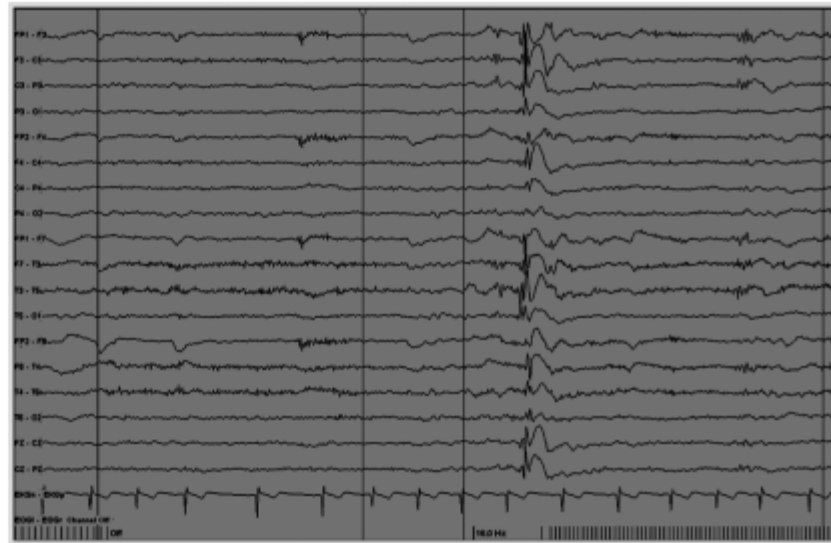
Hartmann et al (*Epilepsia*, March 2015):

- 36 patients with “*SCN1A*-negative fever-associated syndromic epilepsy”.
- Genome-wide screening for copy number variations (CNVs) done.
- Comparative genomic hybridization (CGH) or chromosomal microarray (CMA).
- 13 rare CNVs identified in 8 of the 36 patients (22%).
  - 4 known pathogenic CNVs:
    - 1q21.1 duplication (Dravet), 14q23.3 deletion (GEFS+), 16p11.2 and 1q44 deletion (fever-associated epilepsy with ASD or ID).
  - 3 likely pathogenic CNVs:
    - 3q13.11 duplication (GEFS+), two de novo duplications at 7p14.2 and 18q12.2 (atypical Dravet).
  - 6 CNVs of unknown significance.

### Case 3-7

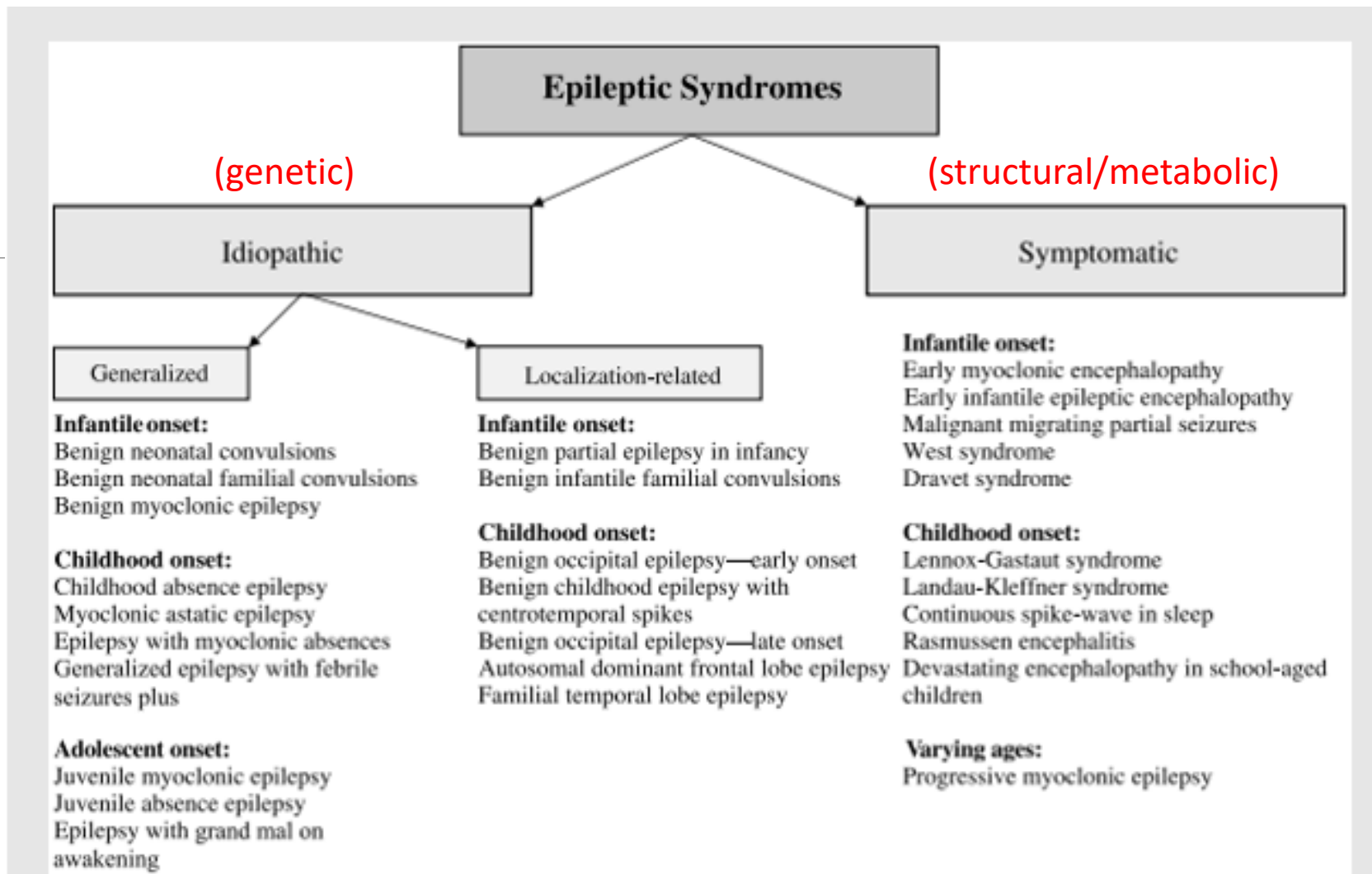
A 7-month-old girl presented with three bouts of status epilepticus. Her first seizure occurred at 4 months, within 24 hours of an immunization. She had twitching of her left face and arm, which progressed to become secondarily generalized and lasted 45 minutes. Her second prolonged seizure was similar and occurred at 6 months during a viral upper respiratory infection. The third occurred during a car ride on a warm summer day and began with right-sided arm and leg twitching, which secondarily generalized and lasted 65 minutes. Her electrolytes, glucose, calcium, metabolic studies, and MRI were normal, and the EEG showed some mild postictal slowing. Her mother had experienced two simple febrile convulsions in infancy. Genetic testing for SCN1A showed a frameshift mutation. She continued to have bouts of status epilepticus every 2 to 3 weeks despite valproic acid and clonazepam and ultimately stiripentol was started, which reduced her bouts of status epilepticus to less than every 6 months. At 24 months, she was clearly delayed with only two words and had some nondisabling myoclonus. Her EEG showed some activation with photic stimulation (**Figure 3-8**). At 3½ years of age, she was found face down in the bathtub and could not be resuscitated.

**Comment.** The history of recurrent bouts of focal-onset prolonged seizures in the first year of life, often triggered by fever, should suggest a diagnosis of Dravet syndrome. This is a clinical diagnosis, although approximately 80% of patients are shown to have mutations in the *SCN1A* gene. Stiripentol, when used in combination with clobazam and valproate, may significantly reduce seizure frequency and duration. The initial EEG may be unremarkable. However, a significant proportion of children will show abnormalities with photic stimulation after 2 years of age. Unfortunately, the mortality rate is significant in this syndrome.



**FIGURE 3-8**

Electroencephalograph of a 2-year-old child with Dravet syndrome showing a small amount of generalized spike-wave induced by photic stimulation.



**FIGURE 3-1** Classification of epileptic syndromes.

# Benign Neonatal Convulsions

---

## **Benign Familial Neonatal Seizures (BFNS)**

- Seizures present during first few weeks of life.
- Brief, but occur 20-30 times per day.
- **Normal** interictal neurologic exam.
- **Family history** of similar neonatal seizures.
- **AD** disorder with 85% penetrance.
- Voltage-gated potassium channels **KCNQ2** and **KCNQ3** on chromosomes 20q and 8q respectively.
- **Favorable outcome** with resolution of seizures in infancy and **normal neurodevelopment**.
- However, up to 8-16% will later develop epilepsy as adults.

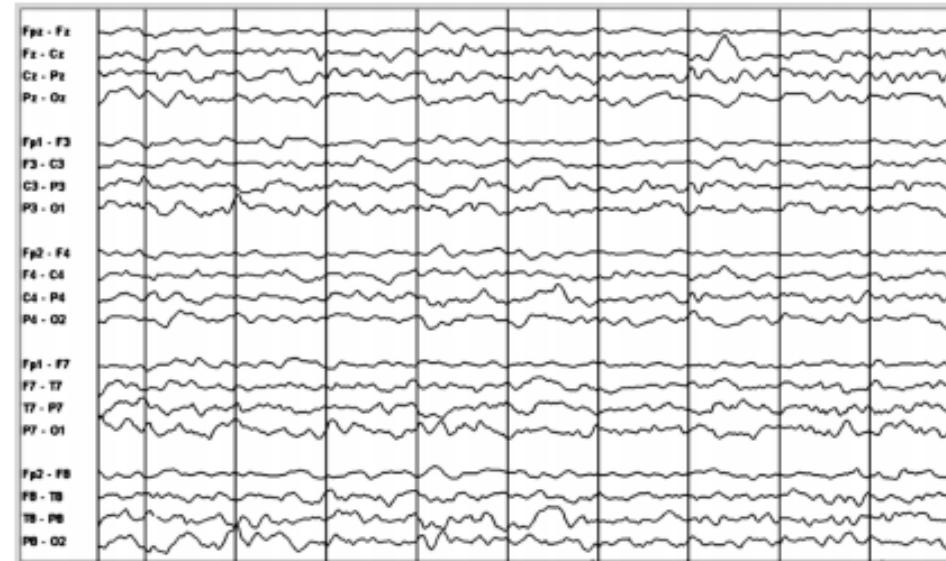## **Benign idiopathic neonatal seizures (BINS)**

- Onset of seizures on fifth day of life (“**fifth day fits**”).
- Otherwise healthy, neurologically appropriate, term neonates.
- Partial clonic seizures, may increase in frequency, and culminate in status epilepticus.
- No specific EEG features.
- No family history of neonatal seizures.
- Favorable prognosis as seizures typically resolve after 24 hours.
- Unlike BFNS, there is **no increased risk** of seizure recurrence in patients with BINS.

### Case 3-1

A healthy, term, 2-week old boy presented to the emergency department with frequent seizures. In between the seizures the infant was alert, interactive, and continued to feed vigorously. A sepsis evaluation was negative. His MRI and EEG (Figure 3-2) were also normal. In spite of this, the baby had many seizures per day that did not respond to multiple antiseizure medications. His grandmother then visited the baby and informed his parents that his father, paternal aunt, and cousin all had similar seizures and went on to have normal growth and development.

**Comment.** BFNS present during the neonatal period in previously healthy term infants. No specific features of the EEG help with the diagnosis. The diagnosis is frequently made when the evaluation for seizures fails to reveal an etiology and there is a family history of neonatal seizures with subsequent normal growth and development. BFNS is an autosomal dominant disorder with 85% penetrance.



**FIGURE 3-2**

Normal drowsy interictal electroencephalograph in a neonate with benign familial neonatal seizures.

# Myoclonic Astatic Epilepsy (MAE) “Doose Syndrome”

---

Idiopathic (genetic) generalized seizure disorder.

Up to 32% of children with MAE **have family** history of epilepsy, inheritance pattern unknown.

- Gene(s) have not yet been implicated.

Rare, occurs 1:10,000 **previously neurodevelopmentally healthy** preschool-aged children.

Multiple seizure types including GTC, myoclonic, absence, **myoclonic astatic**.

- Similar to seizure types seen in patients with Lennox-Gastaut syndrome (LGS).
- Distinguish from LGS based on observation of myoclonic astatic seizures and with EEG.
  - Interictal EEG of LGS demonstrates 1.5-Hz to 2.5-Hz generalized slow spike/wave discharges.
  - EEG of MAE demonstrates **2-Hz to 3-Hz** spike/wave discharges.

Neurodevelopmental arrest is common and **regression** often occurs.

Seizures are often difficult to control despite multiple AEDs.

**Ketogenic diet** is frequently used with good results.

Prognosis is **variable**-- from complete remission to intractable epilepsy with poor cognitive outcome.

- Prognosis is generally more favorable than LGS.

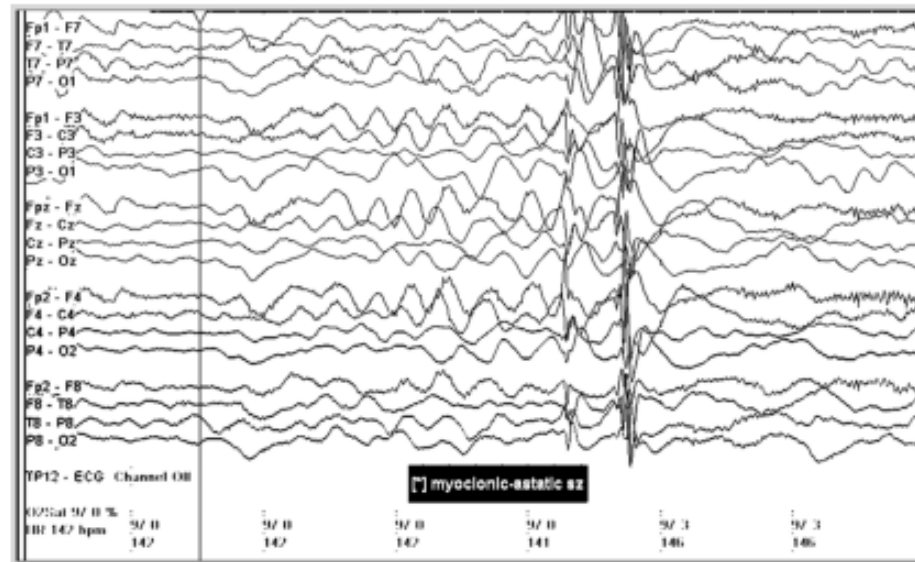


### Case 3-2

A previously well 3-year-old boy presented with a history of two generalized tonic-clonic seizures over 4 days. His EEG was normal, and treatment with oxcarbazepine was started. Two weeks later, he had a cluster of 14 generalized tonic-clonic seizures lasting up to 5 minutes each over a 3-day period. He was admitted to the hospital. Oxcarbazepine was stopped, and valproate was loaded with improvement. Over the next 2 weeks, he developed a new seizure type during which he would jerk forward and fall to the ground. Despite increasing doses of valproate, he continued to have both myoclonic astatic as well as generalized tonic-clonic seizures. His EEG now showed slow spike-wave and some high-amplitude slow waves, and several seizures were recorded (**Figure 3-3**). Clonazepam was added with a marked deterioration in his behavior. He was started on the ketogenic diet with marked improvement of his clinical seizures (**Video Segment 3**).

**Comment.** MAE presents acutely in previously well children. Initial seizure types are often generalized tonic-clonic; however, the characteristic myoclonic astatic seizure follows shortly.

In distinction to LGS, children with MAE have myoclonic astatic rather than atonic seizures, rare or no tonic seizures, normal development preceding seizure onset, lack of fast frontal or generalized polyspike activity in sleep, presence of parietal theta rhythms, and a higher likelihood of photosensitivity on EEG. Although therapeutic strategies are similar for the two disorders, MAE has a more favorable prognosis.



**FIGURE 3-3**

Electroencephalograph of a child with myoclonic astatic epilepsy showing generalized slowing and slow spike-wave with a recorded myoclonic astatic seizure.

# Childhood Absence Epilepsy (CAE)

---

Onset between **4 and 10 years** in neurodevelopmentally healthy children.

Abrupt onset of **impaired consciousness** and unresponsiveness.

Seizures last **~10 seconds**, can occur up to hundreds of times per day.

Provoked by **hyperventilation** in 90% of patients.

EEG shows generalized **3-Hz spike/wave** discharges.

Generally self-limiting with remission of seizures 2-4 years after onset.

- However, seizures persist into adolescence and adulthood in 12 to 32% of cases.
  - 40% of these patients will have GTC seizures as well.

11 to 18% of patients with CAE will develop Juvenile Myoclonic Epilepsy (JME).

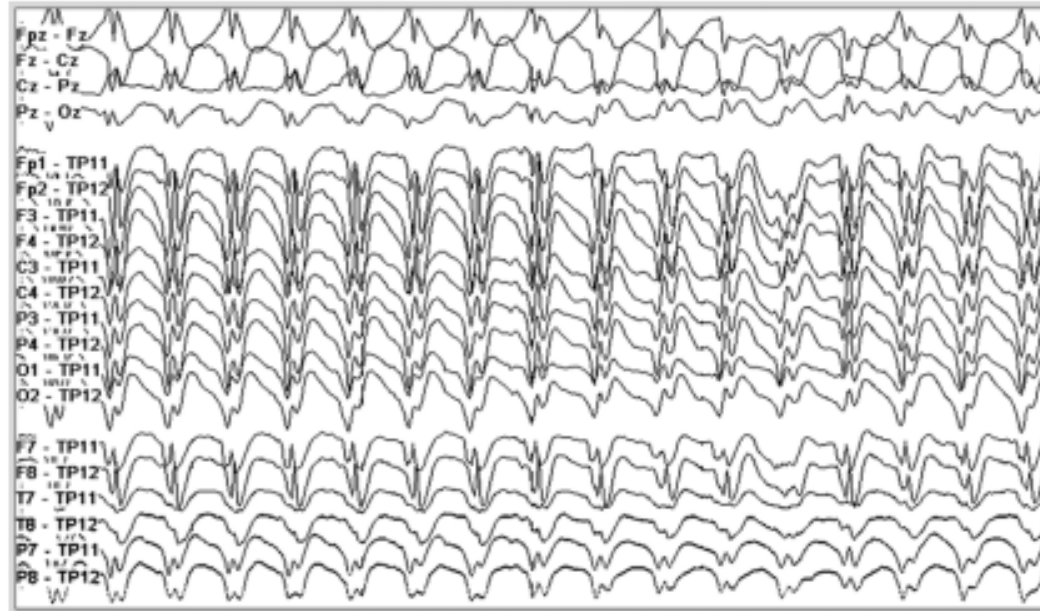
CAE is likely **AD** inheritance with incomplete penetrance. Chromosomes implicated 20q, 16p13.3, 8q24.3.

Treatment-- ethosuximide, valproic acid, lamotrigine. Avoid carbamazepine, oxcarbazepine, phenytoin.

### Case 3-3

A 6-year-old girl with normal growth and development was brought to her pediatrician for evaluation of spells. Her teachers at school were concerned because she frequently appeared to "stare off" throughout the day. She was missing questions on spelling tests and said she did not remember hearing the questions. Her parents had also noticed episodes during which she appeared to "freeze" briefly, and then returned to normal. Her pediatrician was able to elicit one of these events by asking her to hyperventilate. Her mother had a history of similar seizures. The child was treated with carbamazepine for complex partial seizures. However, her spells dramatically increased in frequency, and she was referred to the neurology department. Her EEG demonstrated frequent 3-Hz spike-and-wave discharges, as well as frequent absence seizures (**Figure 3-4**). The carbamazepine was discontinued, and she was treated with ethosuximide. Her seizures resolved. By age 10, ethosuximide was discontinued and she remained seizure free (**Video Segment 1**).

**Comment.** Frequent, brief seizures without postictal symptoms are typical of absence seizures. Seizures can be provoked with hyperventilation in 90% of children with CAE. Most children have remission of their epilepsy within 2 to 6 years of onset. Medications such as phenytoin, carbamazepine, and oxcarbazepine should be avoided because they are ineffective and may precipitate absence status epilepticus.



**FIGURE 3-4**

Generalized 3-Hz spike-and-wave discharge during a typical absence seizure.

# Juvenile Absence Epilepsy (JAE)

---

Similar to CAE, but onset generally **older than 10 years**.

Seizures are **longer** in duration and **less frequent** than CAE.

JAE patients are more likely to have **GTC** seizures.

Interictal EEG in JAE shows **3.5-Hz to 4.0-Hz** spike and polyspike/wave discharges.

JAE also is generally responsive to AEDs, but is more likely to be life-long syndrome.

# Juvenile Myoclonic Epilepsy (JME)

---

Onset of seizures between 12 and 18 years in neurodevelopmentally healthy adolescents.

Seizure types include **absence**, **myoclonic**, **generalized tonic-clonic**.

First seizure type noted is often GTC, provoked by **sleep deprivation**.

History may reveal “staring spells” and myoclonic jerks in the **early morning**.

Routine EEG abnormal in 50 to 75%.

- 4-Hz to 6-Hz generalized atypical spike and polyspike/wave discharges.
- Focal discharges seen in up to 30% of patients.

**Photosensitivity** common, may provoke myoclonic seizure.

Provoking factors include **sleep deprivation**, alcohol consumption, menstruation.

Inheritance is complex--

- classic form is **AD** and linked to chromosome 6p12-11.
- patients with primarily absence seizures linked to chromosomes 15q14 or 6p21.3.
- 2q22-23 and 5q34-34 also linked to JME.

Treatment with valproic acid, levetiracetam, lamotrigine, topiramate, zonisamide.

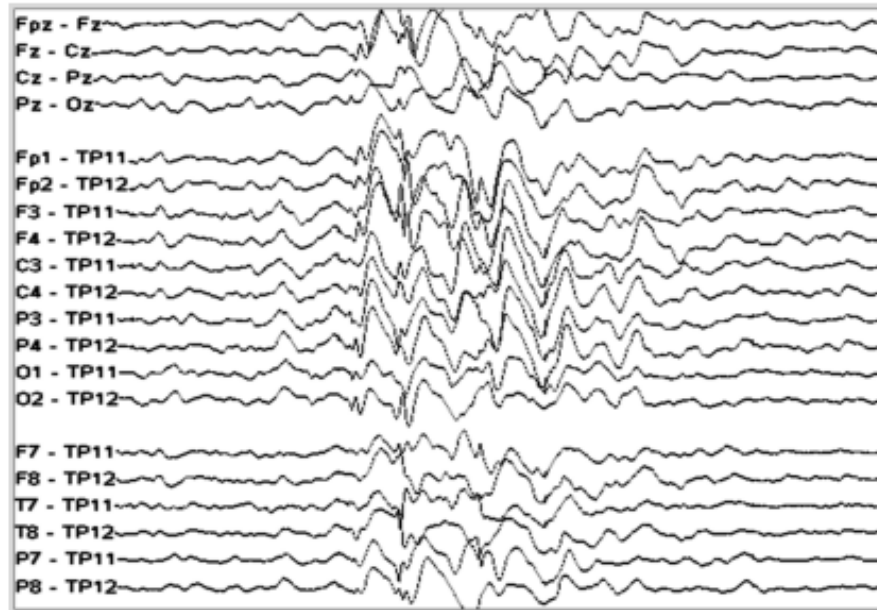
- Avoid carbamazepine, phenytoin, gabapentin-- these make myoclonic seizures worse!

Prognosis generally good but often lifelong syndrome.

### Case 3-4

A 16-year-old previously healthy boy had a generalized tonic-clonic seizure while on vacation with his family. In the emergency department he had a second generalized tonic-clonic seizure. His family acknowledged he had been staying up later than usual because of the vacation. His family also noticed that he frequently dropped his breakfast dishes. As the vacation week progressed, he seemed to be spilling things more frequently. He had had similar myoclonic jerks immediately preceding his generalized tonic-clonic seizure. EEG demonstrated 4-Hz to 6-Hz generalized atypical spike-and-wave discharges and photosensitivity (**Figure 3-5**). He was treated with valproic acid and became seizure free for the next 5 years. He then discontinued valproic acid because of seizure freedom but had recurrence of myoclonic and generalized tonic-clonic seizures shortly thereafter. Valproic acid was restarted but at a lower dose. He remained free of generalized tonic-clonic seizures but had rare myoclonic seizures after sleep deprivation or alcohol consumption. **Video Segment 2** depicts a cluster of myoclonic seizures during photic stimulation.

**Comment.** Children with JME frequently come to medical attention after generalized tonic-clonic seizures. A history of preceding myoclonic and absence seizures must be sought. Valproic acid is the traditional treatment for JME, with an excellent response. However, only 10% of children are able to remain seizure free after discontinuing antiseizure medications.



**FIGURE 3-5**

Interictal generalized atypical spike-and-wave discharge in an adolescent with juvenile myoclonic epilepsy.

**TABLE 3-1 Idiopathic Generalized Epilepsy Syndromes in Infants and Children**

Syndrome	Age at Onset	Clinical	EEG	Genetics	Treatment	Prognosis
● Benign neonatal convulsions	Day 1 to 7, peak day 5 of life	Partial clonic, may migrate Apnea Rare tonic Many progress to status epilepticus	Normal, excessively discontinuous, focal or multifocal discharges	Idiopathic	Phenobarbital Fosphenytoin Benzodiazepines	Excellent, rare recurrence of seizures
● Benign neonatal familial convulsions (BFNC)	Majority during neonatal period, typically during first week of life	Tonic-clonic Apnea Autonomic phenomena Normal behavior interictally	May be normal or show transient changes, including focal epileptiform discharges	Autosomal dominant, 85% penetrance, BFNC1 due to mutation in <i>KCNQ2</i> on 20q13.3, BFNC2 due to mutation in <i>KCNQ3</i> on 8q24	Seizures resolve spontaneously	Seizures usually remit by midinfancy 10% to 16% will later develop epilepsy
Benign myoclonic epilepsy	4 months to 3 years	Myoclonic seizures Absences Rare GTC	Generalized polyspike-and-wave discharges	Unknown, but 31% have a family history	Valproate	Excellent
● Generalized epilepsy with febrile seizures plus	Infancy to adolescence	Febrile seizures beyond age 6 years and afebrile myoclonic, atonic, tonic-clonic, absence, and complex partial seizures	May be normal or may show generalized spike-and-wave or focal discharges	Autosomal dominant, up to 80% penetrance, linked to multiple chromosomes: <i>SCN1B</i> on 19q13, <i>SCN1A</i> on 2q24, and <i>GABRG2</i> on 5q33-q34	Valproate	Variable; most do well, but up to 30% may have more severe epilepsy
● Myoclonic atonic epilepsy	7 months to 8 years, peak 2 to 6 years	Myoclonic Atonic atonic Myoclonic atonic Absences Tonic	Normal at onset Later, slowing of the background and 2-Hz to 3-Hz generalized irregular spike-and-wave discharges	Family history of seizures in 32%	Valproate, ethosuximide, benzodiazepines Lamotrigine may be used to treat GTC seizures Carbamazepine and vigabatrin should be avoided	May be favorable in 50% to 89%, although up to 41% may have borderline IQ or mental handicap, and some will develop intractable epilepsy

continued on next page

**TABLE 3-1** *Continued*

Syndrome	Age at Onset	Clinical	EEG	Genetics	Treatment	Prognosis
● Childhood absence epilepsy	2 to 12 years	More common in girls Many brief seizures per day Staring, behavioral arrest without aura or postictal symptoms	Normal background with 3-Hz generalized spike-and-wave discharges	Possibly autosomal dominant, linked to 20q and 8q24.3	Ethosuximide Valproate Lamotrigine	Patients typically have remission 2 to 6 years after
Eyelid myoclonia with and without absences	2 to 14 years, peak 6 to 8 years	Myoclonia of eyelids, upward deviation of eyes, and retropulsion of the head with or without impairment of consciousness, mainly after eye closure GTC	Frequent high-amplitude 3-Hz to 6-Hz generalized spike- and polyspike-and-wave discharges, typically seen with eye closure	Unknown, but most have a family history of epilepsy	Valproate, ethosuximide, clonazepam, possibly levetiracetam	Myoclonia is resistant to treatment and the syndrome is lifelong, even in those with well-controlled seizures
Perioral myoclonia with absences	2 to 13 years, median 10 years	Absence with ictal perioral myoclonia GTC seizures Frequent absence status epilepticus	Bursts of 4-Hz to 7-Hz generalized, but often asymmetric, spike- and polyspike-and-wave, may have focal discharges, ictal EEG 3-Hz to 4-Hz irregular generalized spike- and polyspike-and-wave discharges	Unknown, but 50% have a first-degree relative with idiopathic generalized epilepsy and absences	Valproate alone or with ethosuximide, lamotrigine, clonazepam; absence status epilepticus should be treated with benzodiazepines	Usually resistant to medication and may be lifelong

*continued on next page*



**TABLE 3-1** *Continued*

Syndrome	Age at Onset	Clinical	EEG	Genetics	Treatment	Prognosis
Epilepsy with myoclonic absences	11 months to 12 years 6 months, mean 7 years	Myoclonic absence seizures GTC seizures Absence Seizures with fall Absence status	Generalized 3 Hz with a strict correlation between EEG discharge and myoclonia	20% have a family history of epilepsy	Valproate with ethosuximide Benzodiazepines Lamotrigine	Epilepsy improves in approximately one-third Presence of GTC seizures is a poor prognosis
Juvenile myoclonic epilepsy	Late childhood to late adolescence	Absence seizures in childhood Myoclonus early adolescence GTC adolescence	Normal background with 3-Hz to 4-Hz generalized atypical spike-and-wave discharges	Complex inheritance linked to 6p, 18, 15q14, and 8q23.3-q24.1	Valproate Lamotrigine Levetiracetam	Response to AED is usually good, but lifelong treatment is frequently required
Juvenile absence epilepsy	Adolescence	Daily brief absence seizures, fewer than childhood absence epilepsy GTC seizures	Normal background with 3-Hz to 4-Hz generalized spike-and-wave discharges	Possible localization to 21q22.1	Valproate Lamotrigine Ethosuximide	Response to AED is usually good, but lifelong treatment is frequently required
Epilepsy with grand mal on awakening	6 to 35 years	Seizures occur shortly after waking up, may be associated with absence or myoclonic seizures	Slow background, generalized spike-and-wave discharges, photosensitivity	Thought to be genetic; 3.3% have a first-degree relative with epilepsy		Response to AED is good, but relapse occurs with AED discontinuation and sleep deprivation

EEG = electroencephalograph; GTC = generalized tonic-clonic; AED = antiepileptic drug.

# Benign Occipital Epilepsy, early

---

**Early-onset** benign childhood epilepsy with occipital paroxysms  
“**Panayiotopoulos Syndrome**” (PS)

Most commonly in preschool-aged children but can occur anytime between 1 and 14 years of age.

Seizures consist of **autonomic** symptoms including nausea, emesis, retching, pallor, urinary incontinence, hypersalivation. Consciousness is preserved.

Seizure can progress to gaze deviation, speech arrest, convulsive activity, with associated loss of awareness.

Autonomic symptoms can be prolonged-- “autonomic status epilepticus”.

Interictal EEG shows multifocal, high-amplitude epileptiform discharges. May also have **occipital epileptiform discharges**, which are suppressed with eye opening.

Initially may be difficult to treat, but **spontaneous remission** occurs within 1-2 years in 90% of patients.

# Benign Occipital Epilepsy, late

---

**Late-onset** childhood epilepsy with occipital paroxysms  
“Idiopathic childhood occipital epilepsy of Gastaut”

Occurs in school-aged children (as opposed to preschool-aged children with early-onset).

**Visual hallucinations** followed by gaze deviation, ipsilateral head deviation, possible secondary generalization.

Awareness is maintained until gaze deviation occurs.

Ictal and post-ictal **headache** are common.

EEG is similar to that of early-onset benign occipital epilepsy (PS).

Remission occurs in only 50-60% within 2-4 years.

Treatment with carbamazepine.

# Benign Childhood Epilepsy With Centrotemporal Spikes (BCECTS)

---

“Benign Rolandic Epilepsy”

Most common idiopathic partial epilepsy.

Onset between 4-10 years.

**Nocturnal** seizures consisting of perioral paresthesias, ipsilateral facial myoclonus, salivation, speech arrest, guttural noises.

Seizure may spread to include ipsilateral or generalized convulsions.

EEG shows high-amplitude centrotemporal spikes, activation during sleep.

Likely **AD** inheritance with incomplete penetrance.

- involvement of chromosomes 1q and 15q14.

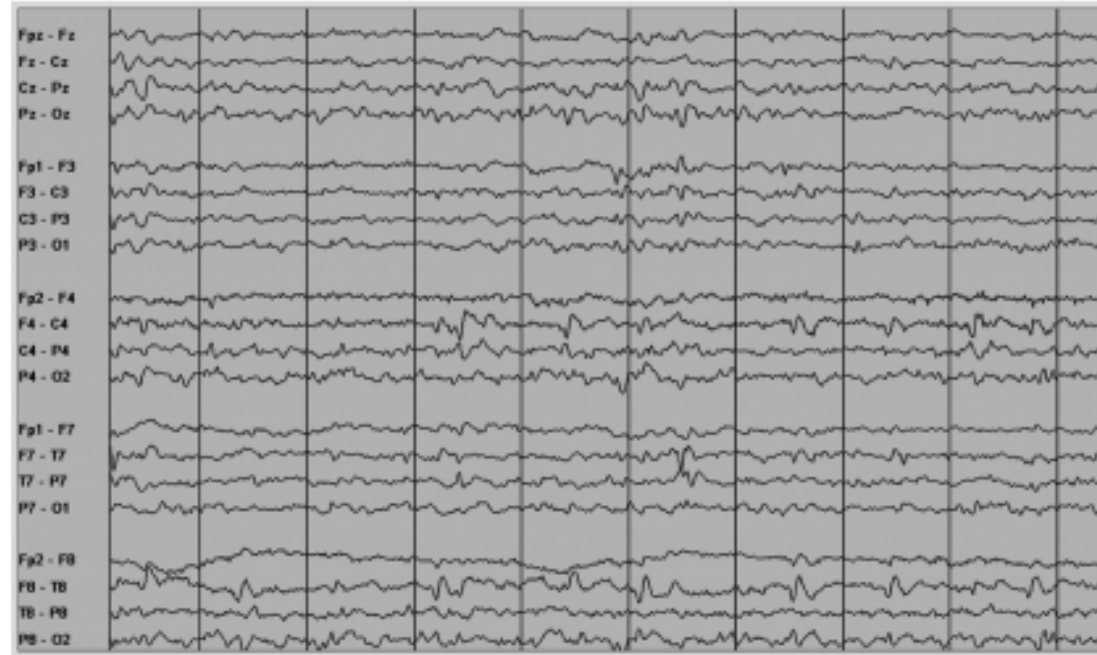
Typically easily controlled with AEDs. Medication may not be necessary.

Spontaneous remission by age 17 years or earlier.

### Case 3-5

A 10-year-old healthy boy had been on vacation with his family. While sharing a hotel room, his family was awakened by the boy sitting up and making strange sounds. He was noted to have salivation and twitching of the right side of his face that seemed to spread to his right arm. Shortly thereafter, he returned to baseline. Six months later, he had a similar event. However, this seizure was longer and progressed to a generalized tonic-clonic seizure. His EEG demonstrated spikes over the bilateral centrotemporal head regions with increased activation during sleep (Figure 3-6). His parents declined treatment for their son because his older brother had similar seizures that he outgrew.

**Comment.** BCECTS presents with nocturnal partial seizures involving the rolandic area, the lower face, and occasionally the hand. The seizures are typically brief but may secondarily generalize. BCECTS is likely inherited through a complicated inheritance pattern. Children with BCECTS usually have infrequent seizures that are predominantly nocturnal. Therefore, medication may not be indicated.



**FIGURE 3-6**

Interictal centrotemporal spike-and-wave discharges in a child with benign childhood epilepsy with centrotemporal spikes.

**TABLE 3-2 Idiopathic Partial Epilepsy Syndromes in Infants and Children**

Syndrome	Age at Onset	Clinical	EEG	Genetics	Treatment	Prognosis
Benign infantile familial convulsions	3.5 to 12.0 months	Psychomotor arrest, eye deviation, cyanosis, limb jerks in clusters of 5 to 10 per day, with or without secondary generalization	Normal or show occipitoparietal spike and wave; ictal: focal discharge with spread	Heterogeneous genetics possibly linked to 19q11-q13 and 16p12-q12, with 70% penetrance	If necessary, carbamazepine, phenobarbital, valproate, zonisamide	Excellent; seizures resolve without recurrence and development is typically normal
● Benign partial epilepsy in infancy	3 to 20 months, mean 9.5 months	Staring, loss of consciousness, cyanosis, behavioral arrest, subtle convulsions, with or without secondary generalization	Normal interictally; ictal: focal low-voltage fast or sharp alpha and theta waves	Family history of febrile, afebrile seizures, or benign infantile familial convulsions present in up to 50%	If necessary, carbamazepine or phenobarbital	Seizures resolve by 2 to 3 years of age, normal development
● Childhood epilepsy with occipital paroxysms—early onset	1 to 14 years, typically 3 to 6 years	Ictal autonomic symptoms including nausea, vomiting, pallor, tachycardia, followed by confusion; 33% to 50% have partial status epilepticus; some have secondary generalization	Multifocal, high amplitude, sharp waves, maximal occipital	Probably genetic; reported siblings with similar seizures, benign childhood epilepsy with centrotemporal spikes	Most do not require antiseizure medication treatment	Excellent; most have infrequent seizures that resolve in 1 to 2 years; risk of adult epilepsy is the same as the general population
● Benign childhood epilepsy with centrotemporal spikes	1 to 14 years, typically 7 to 10 years	Hemifacial sensorimotor seizure with spread to ipsilateral hand; progression to hemiconvulsion or generalized tonic-clonic in 50%	Centro-temporal spikes activated by drowsiness and sleep	Possibly linked to 15q14; EEG findings are autosomal dominant with age-dependent penetrance	Most do not require antiseizure medication treatment	Excellent; most resolve before age 16 years

continued on next page

**TABLE 3-2** *Continued*

Syndrome	Age at Onset	Clinical	EEG	Genetics	Treatment	Prognosis
<ul style="list-style-type: none"> <li>Childhood epilepsy with occipital paroxysms—late onset</li> </ul>	3 to 15 years, typically 8 to 11 years	Visual hallucinations, ictal blindness, then eye deviation, loss of awareness and convulsive activity; postictal headache	Occipital spikes, +/- centrottemporal, frontal, and generalized discharges	Rare family history of same seizure type, but family history of epilepsy and migraine is increased	>90% respond to carbamazepine	50% to 60% resolve in 2 to 4 years, remainder continue to have visual and infrequent generalized tonic-clonic seizures
Autosomal dominant frontal lobe epilepsy	Mean age of onset 11 years	Seizures while falling asleep or awakening; aura of fear, shivering, then hyperkinesia in clusters with or without loss of consciousness	Normal or frontal spikes	Autosomal dominant, 70% penetrance, related to <i>CHRNA4</i> on 20q13.2, <i>CHRN2</i> on 1p21, and other nicotinic acetylcholine receptor genes on 15q	Carbamazepine	Usually respond well to antiseizure medications
Familial temporal lobe epilepsy	Second or third decade	<i>Lateral:</i> simple partial seizures with acoustic and visual hallucinations, some secondarily generalize <i>Mesial:</i> autonomic aura, déjà vu, then complex partial seizure	Epileptiform activity over temporal areas	Autosomal dominant, some linked to 10q22-q24	Carbamazepine	Most respond well to antiseizure medications

# West Syndrome

---

Triad of **infantile spasms**, **hypsarhythmia**, psychomotor **delay**.

Affects 1 per 1900 to 3900 infants. Most common epileptic encephalopathy.

Peak age of onset is 4 to 8 months.

Semiology of spasms:

- Transient contraction of trunk, neck, extremities, followed by brief tonic component.
- Flexor, extensor, or mixed.
- Several clusters per day.
- Asymmetric spasms suggest focal cortical lesion.

Characteristic EEG finding of **hypsarhythmia**-- disorganized, slow, high-voltage multifocal epileptiform discharges.

Etiologies include malformations of cortical development, neurocutaneous disorders (TS), inborn errors of metabolism, mitochondrial disease, ischemia, infection, trauma.

Psychomotor **delay** and developmental **regression** are common.

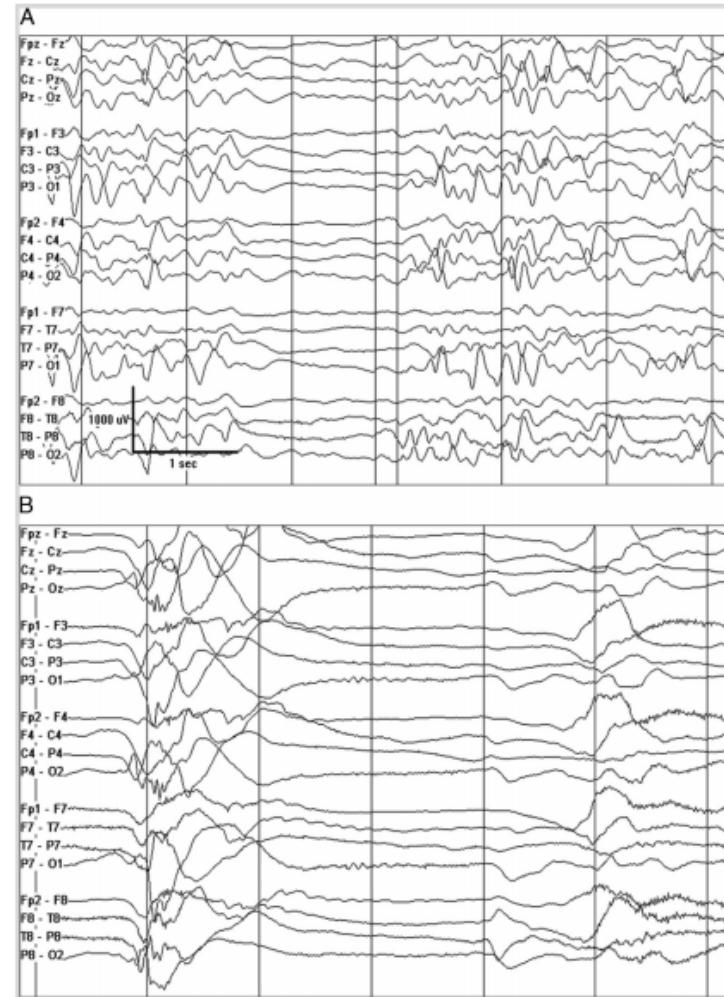
Treatment-- steroids, corticotropin (ACTH), vigabatrin (especially in TS patients), valproic acid, topiramate, levetiracetam.



### Case 3-6

A previously healthy 7-month-old infant girl presented with recurrent clusters of spells during which she suddenly flexed at the trunk and neck and extended her arms. Over the past month, her spells had become more frequent and she was no longer rolling over or laughing like she could previously (Video Segment 7).

**Comment.** This infant is presenting with infantile spasms. Her interictal EEG demonstrates a slow, high-amplitude, poorly organized background with multifocal sharp waves and electrodecrement, consistent with hypsarrhythmia (Figure 3-7). In addition, she now has developmental regression and delay. The triad of infantile spasms, hypsarrhythmia, and developmental delay are consistent with West syndrome. In order to improve developmental outcome, it is important to recognize and treat infantile spasms early.



**FIGURE 3-7**

A, Interictal EEG in a child with infantile spasms demonstrating a slow, poorly organized, high-amplitude background with multifocal sharp waves and electrodecrement, consistent with hypsarrhythmia.

B, Ictal EEG in a child with infantile spasms demonstrating a high-amplitude generalized sharp wave followed by electrodecrement.

# Lennox-Gastaut Syndrome

---

Triad -- **multiple seizure** types, interictal EEG pattern of diffuse slow spike/wave complexes, cognitive dysfunction.

Onset in preschool years.

Two-thirds have existing brain abnormalities (hypoxic ischemic injury, malformations of cortical development, neurocutaneous disorders, etc.)

1.9 to 2.1 per 100,000 children.

6 to 7% of pediatric intractable epilepsy.

Intractable drop seizures common.

EEG shows 1.5-Hz to 2.5-Hz polyspike and spike/wave discharges on slow background.

Medically refractive

**Ketogenic diet**, vagal nerve stimulation (VNS), corpus callostomy.

# Rasmussen Encephalitis

---

Intractable focal epilepsy.

Progressive atrophy in affected hemisphere.

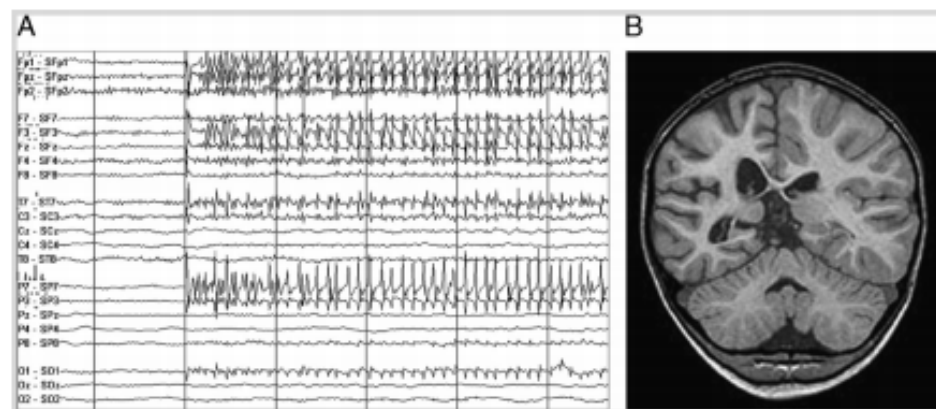
Seizures are refractory to multiple AEDs.

**HEMISPHERECTOMY!**

### Case 3-9

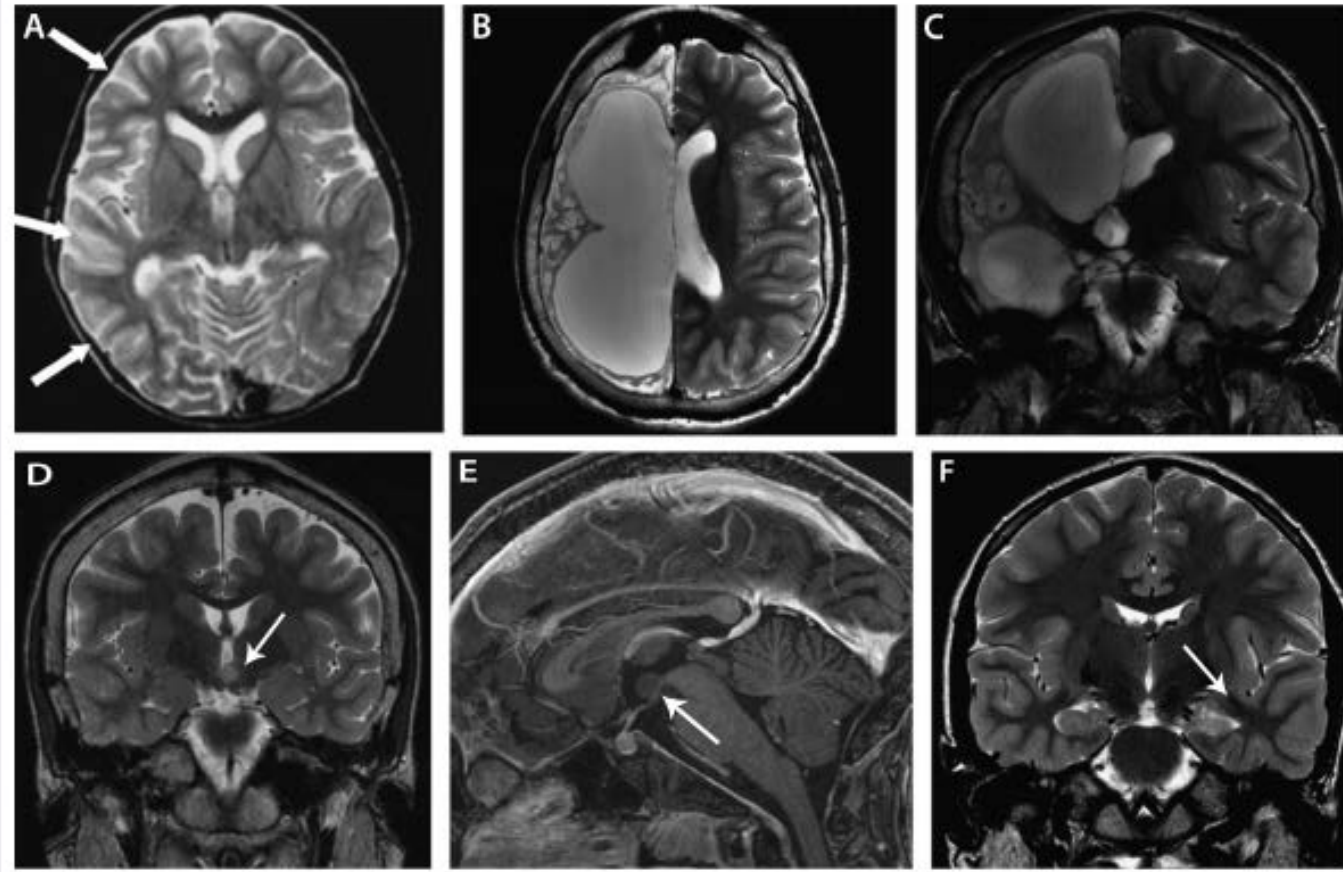
A 4-year-old girl presented with a 3-year history of focal seizures that started with rhythmic twitching of her left arm, followed by left face. At times, they were associated with loss of awareness, and they were rarely secondarily generalized. Over time, seizures increased in frequency and duration to the point they were occurring multiple times per day. She had gradual onset of a left hemiparesis over the past 2 months. On examination, she was noted to have arrhythmic twitching of her left hand and face. Seizures had persisted despite treatment with five antiepileptic drugs (Video Segment 6).

**Comment.** This young girl had epilepsy partialis continua of her left hand and face. Her history of progressive seizures and hemiparesis is suggestive of Rasmussen encephalitis. Her MRI showed right hemispheric atrophy (Figure 3-10), which had not been present 18 months earlier. This condition is notoriously resistant to antiepileptic drugs. While immunotherapy may result in transient response, most children ultimately require hemispherectomy. This girl underwent hemispherectomy 2 months after video was obtained and has remained seizure free.



**FIGURE 3-10**

A, Ictal EEG in a child with Rasmussen encephalitis with a focal motor seizure, demonstrating rhythmic muscle artifact that corresponded with frequency of hemifacial clonic seizure, but no EEG correlate. B, MRI (coronal T1) demonstrates right hemispheric atrophy.



**FIGURE 1-4**

Epilepsies secondary to a structural cause. *A*, Serial T2-weighted brain MRI showing changes over time in untreated Rasmussen syndrome. Earliest abnormal MRI at 3 years 2 months of age during the acute phase shows increased cortical signal (*arrows*). *B*, *C*, MRIs at 13 years 9 months in the residual phase show severe unilateral atrophy of the entire right hemisphere with normal signal intensity. *D*, Brain MRI of a 10-year-old girl with pharmacoresistant epilepsy with gelastic seizures secondary to hypothalamic hamartoma. This is a T2 fast-spin echo, coronal view, and *E*, postcontrast T1 inversion-recovery fast-spin gradient echo, sagittal view, showing a lesion centered in the left aspect of the hypothalamus and extending into the third ventricle (*arrows*). *F*, Brain MRI performed on a 3-Tesla scanner for presurgical evaluation of an 11-year-old boy with pharmacoresistant epilepsy with focal seizures arising from the left temporal lobe. This is a T2 fast-spin echo, coronal view, showing asymmetrical volume loss of the left medial temporal lobe with hyperintensity and obscuration of the hippocampal internal architecture (*arrow*).

Panels A, B, and C with permission from Millichap J J, Goldstein J L, *Neurology*.<sup>38</sup> © 2010, American Academy of Neurology. [www.neurology.org/content/75/20/e85.full](http://www.neurology.org/content/75/20/e85.full).

**TABLE 3-3 Symptomatic Epilepsy Syndromes in Infants and Children**

Syndrome	Age at Onset	Clinical	EEG	Etiology	Treatment	Prognosis
Early myoclonic encephalopathy	Birth to first few weeks	Prominent fragmentary myoclonus  Partial seizures with eye deviation and autonomic signs  Tonic spasms may develop later  Hyporesponsive, hypotonic infant	Suppression burst without EEG correlate to myoclonus	Mostly unknown  Metabolic disorder is rarely found	No effective therapies	Very poor; high mortality in first few years of life
Early infantile epileptic encephalopathy	First weeks to months	Tonic spasms  Partial seizures	Suppression burst	Malformation of cortical development  Some unknown	Vigabatrin, zonisamide, or corticotropin may be helpful, many intractable to AEDs  Epilepsy surgery if a focal malformation is present	Poor
Malignant migrating partial seizures in infancy	First 7 months	Focal motor seizures often with apnea, cyanosis, flushing  Often cluster  May become secondarily generalized with increasing age	Slow background and multifocal discharge  Ictally, see theta rhythms from multiple sites	Unknown	Usually intractable to AEDs  Bromides or stiripentol and clonazepam may rarely help	Very poor
West syndrome	Peak 4 to 7 months	Epileptic spasms in clusters, most commonly on awakening	Hypsarrhythmia	Multiple—see text	First line: corticotropin, steroid, or vigabatrin  Second line: valproate, topiramate, benzodiazepines, ketogenic diet	Often poor but depends on etiology

**TABLE 3-3** *Continued*

Syndrome	Age at Onset	Clinical	EEG	Etiology	Treatment	Prognosis
● Dravet syndrome	First year of life	Recurrent, prolonged focal or generalized tonic-clonic seizures, often triggered by fever, infection, immunizations, bathing  Myoclonic seizures and absences later in course	Often normal initially  Later, slow background, multifocal or generalized polyspike-wave discharge	<i>SCN1A</i> gene mutation on chromosome 2	First line: Valproate and clobazam with stiripentol added if these are not effective, ketogenic diet  Second line: topiramate, levetiracetam, zonisamide	Often poor  Mortality 16% to 18%—SUDEP, status, drowning
● Lennox-Gastaut syndrome	2 to 8 years, peak 3 to 5 years	Multiple types of generalized seizures including tonic, atonic, atypical absence, myoclonic  Developmental delay  Most children have preexisting neurologic disability	Frontally predominant slow spike  In sleep, see fast, frontally predominant 10-Hz rhythmic spike activity	Multiple	Early use of the ketogenic diet should be considered  First line AEDs: valproate, lamotrigine, topiramate	Seizures often refractory  Mental handicap in 80%
Landau-Kleffner syndrome	3 to 8 years	Acquired auditory agnosia  Three-fourths have seizures—partial motor seizures affecting lower face and upper extremity most common	Centrottemporal sharp waves that markedly increase in sleep	Usually idiopathic	Oral steroids, high-dose diazepam	EEG changes and seizures resolve in mid to late childhood but children may be left with language impairment
Continuous spike-wave in sleep	3 to 8 years	More global regression with partial and generalized (atypical absence, atonic, generalized tonic-clonic, but not tonic) seizures	Frontal and multifocal sharp waves that become nearly continuous in sleep	Often symptomatic of underlying brain insult	Oral steroids or high-dose diazepam	EEG changes and seizures improve or resolve in mid to late childhood, but children are often left with cognitive impairment

**TABLE 3-3** *Continued*

Syndrome	Age at Onset	Clinical	EEG	Etiology	Treatment	Prognosis
● Rasmussen encephalitis	18 months to young adulthood	Progressively worsening focal seizures, epilepsy partialis continua, progressive hemiparesis and atrophy of affected hemisphere	Hemispheric slowing, multifocal epileptiform discharges are widespread over affected hemisphere and may be bilateral	Immune-mediated but details poorly understood	Immunotherapy can be tried, but most children ultimately undergo hemispherectomy	After hemispherectomy, two-thirds are seizure free; cognitive deterioration stabilizes, but hemiparesis is permanent (although children can ambulate)
Devastating encephalopathy in school-aged children	4 to 11 years	Intractable convulsive status epilepticus with fever but no intracranial infection that is followed by intractable temporal lobe epilepsy	Recurrent, often multifocal seizures with status epilepticus	Unknown	No effective treatments reported	Very poor; children are left with intractable partial epilepsy and cognitive delay
● Progressive myoclonic epilepsy	Infancy to adulthood	Progressive myoclonus, generalized tonic-clonic and other seizures, mental deterioration, cerebellar dysfunction	Slow background with generalized spike- and polyspike-and-wave discharge	Multiple metabolic and neurodegenerative conditions	AEDs may help but do not provide complete control; valproate, clonazepam, zonisamide, levetiracetam	Progressive but rapidity depends on etiology

EEG = electroencephalograph; AED = antiepileptic drug; SUDEP = sudden unexplained death in epilepsy.



# Advanced Epilepsy Panel



**Test Code:** 5000

**Specimen Requirements:** 10 mL room temperature EDTA whole blood (lavender-top tube)

Stability at room temperature is 48 hours; ship on day of collection. Avoid freezing.

**CPT Codes\*:** 81302, 81403, 81404 (x9), 81405 (x12), 81406 (x18), 81407 (x4), 81408 (x3), 81479

Table. Genes Tested in the Epilepsy Advanced Sequencing Evaluation, by Associated Phenotype<sup>a</sup>

Epilepsy Phenotype <sup>b</sup>	Genes Tested
Generalized, absence, focal, and myoclonic epilepsies (5001)	ALDH7A1, CACNA1A, CASR, CHRNA2, CHRNA4, CHRN2, CSTB, DEPDC5, EFHC1, EPM2A, GABRA1, GABRB3, GABRD, GABRG2, GRIN2A, KCNMA1, KCNQ2, KCNQ3, KCNT1, KCTD7, LGI1, MBDS, ME2, NHLRC1, PCDH19, PRICKLE1, PRICKLE2, PRRT2, SCARB2, SCN1A, SCN1B, SCN2A, SCN9A, SLC2A1, SLC4A10, TBC1D24
Epileptic encephalopathies (5002)	ARHGEF9, ARX, CDKL5, CNTNAP2, FOXG1, GABRG2, GRIN2A, KCNT1, MECP2, NRXN1, PCDH19, PNKP, RNASEH2A, RNASEH2B, RNASEH2C, SAMHD1, SCN1A, SCN1B, SCN2A, SCN8A, SCN9A, SLC25A22, SLC2A1, SLC9A6, SPTAN1, STXBP1, SYNGAP1, TCF4, TREX1, UBE3A, ZEB2
Neuronal migration disorders (5003)	ARFGEF2, ARX, COL18A1, COL4A1, CPT2, DCX, EMX2, FGFR3, FKRP, FKTN, FLNA, GPR56, LAMA2, LARGE, PFAH1B1, PAX6, PEX7, POMGNT1, POMT1, POMT2, PQBP1, RAB3GAP1, RELN, SNAP29, SRPX2, TUBA1A, TUBA8, TUBB2B, WDR62
Epilepsy in X-linked intellectual disability (5004)	ARHGEF9, ARX, ATP6AP2, ATRX, CASK, CDKL5, CUL4B, DCX, FGD1, GPC3, GRIA3, HSD17B10, KDM5C, MECP2, OFD1, OPHN1, PAK3, PCDH19, PHF6, PLP1, PQBP1, RAB39B, SLC9A6, SMC1A, SMS, SRPX2, SYP
Neuronal ceroid lipofuscinosis (5005)	CLN3, CLN5, CLN6, CLN8, CTSD, DNAJCS, KCTD7, MFSD8, PPT1, TPP1
Epilepsy with migraine (5006)	ATP1A2, CACNA1A, NOTCH3, POLG, PRRT2, SCN1A, SLC2A1
Syndromic disorders (5007)	ATP2A2, ATP6V0A2, CCDC88C, CLCNKA, CLCNKB, VPS13B, KCNA1, KCNJ1, KCNJ10, KIAA1279, LBR, LGI1, MLL2, NIPBL, PANK2, SERPINI1, PIGV, PLA2G6, RAI1, SETBP1, SMC3, SYNGAP1, TBX1, TSC1, TSC2, VPS13A
Infantile spasms (5008)	ARX, CDKL5, FOXG1, GABRB3, GRIN2A, MEF2C, SCN2A, SLC25A22, SPTAN1, STXBP1

<sup>a</sup> Some genes in this panel are associated with more than 1 epilepsy phenotype.

<sup>b</sup> Testing for the groups of genes associated with each phenotype may be ordered separately, using the test codes listed in parentheses, for patients whose phenotypes suggest specific syndromes.

# References

---

1. Febrile Seizures: Guideline for the Neurodiagnostic Evaluation of the Child With a Simple Febrile Seizure. American Academy of Pediatrics Subcommittee on febrile seizures. *Pediatrics* Vol. 127 No. 2 February 1, 2011.
2. Hofert SM, Burke MG. Nothing Is Simple About a Complex Febrile Seizure: Looking Beyond Fever as a Cause for Seizures in Children. *Hospital Pediatrics*. Vol. 4 No. 3 May 1, 2014.
3. Annegers JF et al. Factors prognostic of unprovoked seizures after febrile convulsions. *New England Journal of Medicine*. 1987;316(9):493-498.
4. Sales JW et al. Practive variability in the management of complex febrile seizures by pediatric emergency physicians and fellows. *CJEM*. 2011;13(3):145-149.
5. Patel AD, Vidaurre J. Complex febrile seizures: a practical guide to evaluation and treatment. *Journal of Child Neurology*. 2013;28(6):762-767.

# References cntd.

---

6. Wirrell E, Nickels, KC. Pediatric Epilepsy Syndromes. *Continuum Lifelong Learning Neurol.* 2010;16(3):57-85.
7. Glauser T, Loddenkemper T. Management of Childhood Epilepsy. *Continuum Lifelong Learning Neurol.* 2013;19(3):656-681.
8. Berg AT, Millichap JJ. 2010 Revised Classification of Seizures and Epilepsy. *Continuum Lifelong Learning Neurol.* 2013;19(3):571-597–681.
9. Hartmann C et al. Investigating the genetic basis of fever-associated syndromic epilepsies using copy number variation analysis. *Epilepsia.* 2015 Mar;56(3):e26-32.
10. Brunklaus A, Zuberi SM. Dravet syndrome—from epileptic encephalopathy to channelopathy. *Epilepsia.* 2014 Jul;55(7)979-84.
11. Scheffer IE et al. Dravet syndrome or genetic (generalized) epilepsy with febrile seizures plus? *Brain Dev.* 2009 May;31(5):394-400.